

Coccidiosis in Poultry



Dr. Subhradal Nath

Assistant Professor

Department of Veterinary Parasitology

C.V.Sc. & A.H., Jabalpur, NDVSU

Introduction

- Poultry coccidiosis is one of the most important disease
- Generates great economic losses due to mortality, reduced body weight plus the expenses related to preventive and therapeutic control
- Poultry coccidia are generally host specific, and the different species parasitize specific parts of the intestine.
- However, in game birds, including quail, the coccidia may parasitize the entire intestinal tract. Coccidia are distributed worldwide in poultry, game birds reared in captivity, and wild birds
- Coccidial infection is self-limiting

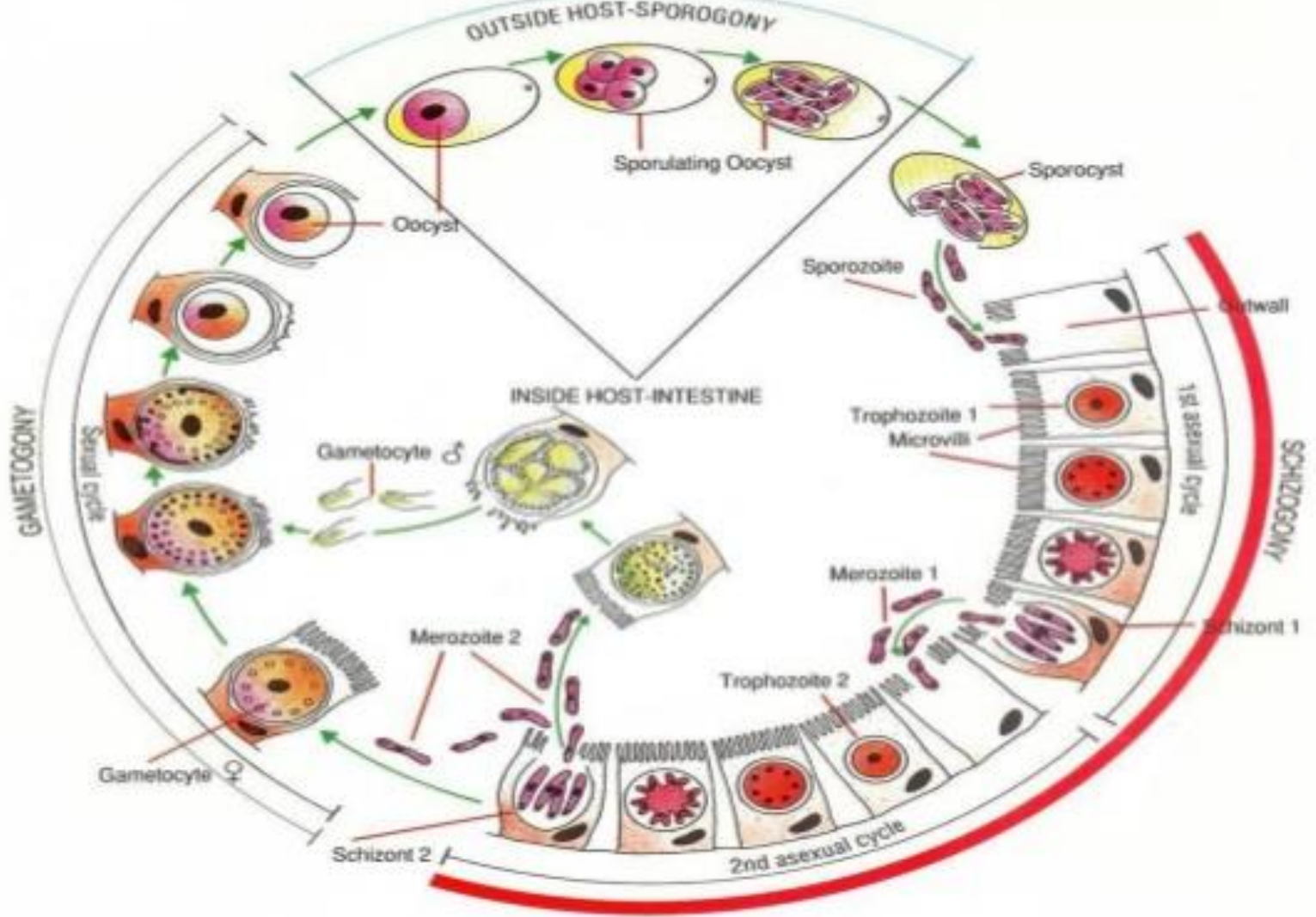
Etiology

- Nine species of *Eimeria* have been described that infect *Gallus gallus* var. *domesticus* at various locations along the intestinal tract: *E. acervulina*, *E. brunetti*, *E. hagani*, *E. maxima*, *E. mitis*, *E. mivati*, *E. necatrix*, *E. praecox*, and *E. tenella*.
- Except *E. hagani* and *E. mivati* the other 7 causes clinical coccidiosis

Life cycle

1. The life-cycle is short and starts with the bird ingesting sporulated oocysts
2. The sporulated oocysts contain four sporocysts, each containing two sporozoites and the mechanical and acidic environment in the gut result in the release of these sporocysts and sporozoites into the gut.
3. The sporozoites invade the duodenal mucosa epithelial cells before undergoing phases of growth and multiplication with periodic release of merozoites into the gut.
4. Merozoites develop within the duodenal cells as gametes, in the form of both macro- and microgametocytes
5. These develop into a zygote and then an oocyst which is shed in the faeces
6. These oocysts require moist conditions to undergo sporulation, a process that requires oxygen and takes about 24 hours, at which point they become infective.

Life Cycle



Coccidiosis Lifecycle in Poultry

First generation **merozoites** are released from ruptured gut cells and invade neighbouring cells, then multiply further

Gut cells

Sporozoites

Merozoites

Gametes

Oocyst

Merozoites

Birds ingest infective sporocyst, which releases sporozoites which invade gut cells. These develop and multiply asexually to produce merozoites

Parts of the gut wall are packed with parasites which differentiate into male and female sex cells called **gametes**. The male fertilizes the female to form the zygote, or **Oocyst** which is shed through the faeces

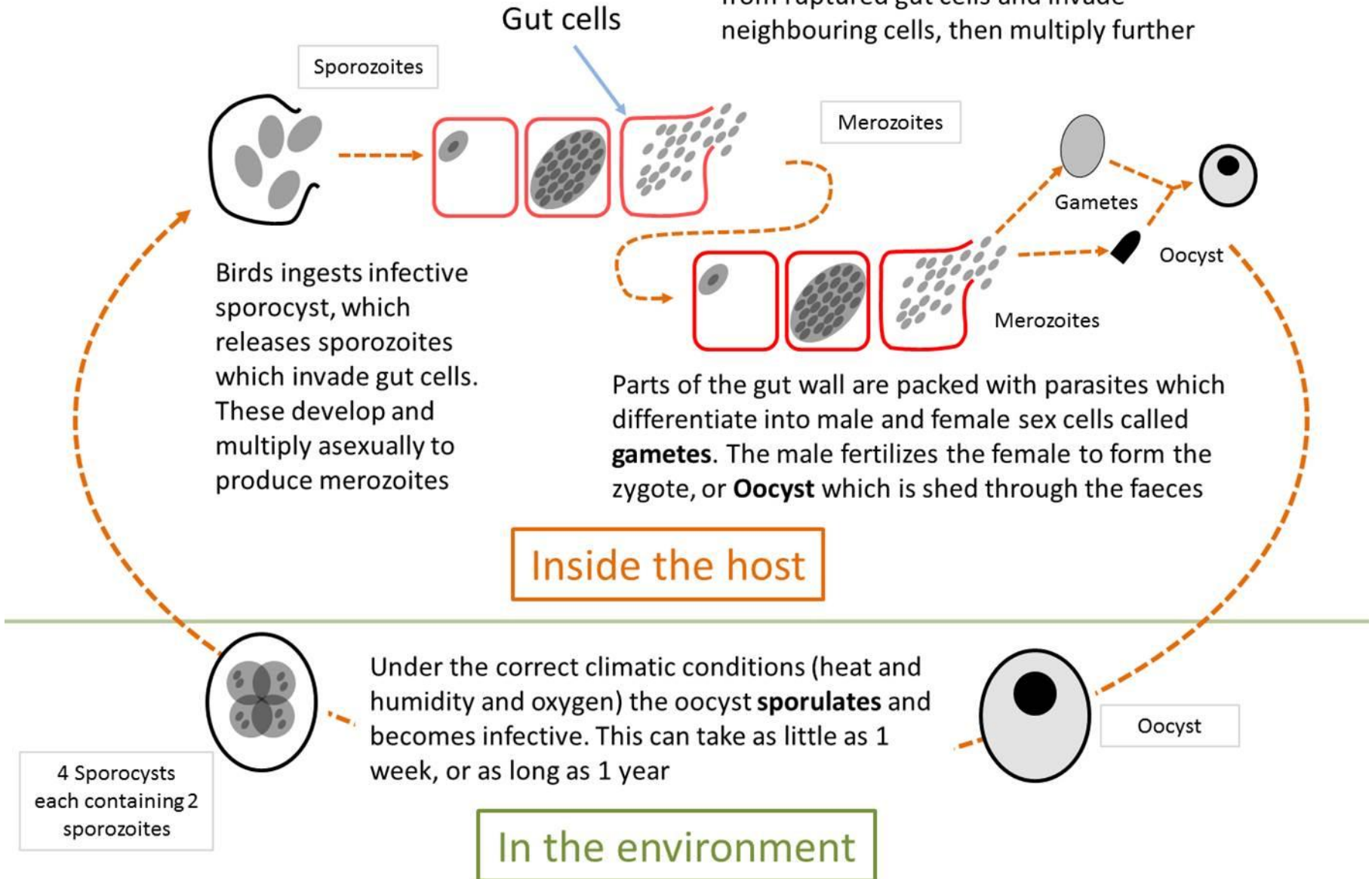
Inside the host

Under the correct climatic conditions (heat and humidity and oxygen) the oocyst **sporulates** and becomes infective. This can take as little as 1 week, or as long as 1 year

4 Sporocysts each containing 2 sporozoites

In the environment

Oocyst



Eimeria in Chickens - Gut Location

BREEDERS

BROILERS




E. aceroulina

E. maxima

E. necatrix

E. tenella

E. brunetti



Prepatent Period (Days)

5

7

8

7

6

Transmission

- Young chickens pick up the infection from contaminated premises (soil, houses, utensils, etc.).
- These premises may have been contaminated previously by other young infected birds or by adult birds that have recovered from the condition.
- Wet areas around water fountains are a source of infection. Oocysts remain viable in litter for many months.
- In this way, they can contaminate a farm from year to year. Oocysts are killed by freezing, extreme dryness and high temperatures.

Prediposing Factors

- **High stocking density**
- **Bad quality litter and lighting schedule**
- **Antinutritional factors (ANF's) in the feed,**
- **Brooder and grower management**
- **overcrowding**
- **Number of oocysts ingested by the bird and strain of coccidia**
- **Environmental factors** affecting the survival of the oocysts. *Viz* Season
- **Site of development within the host**
- **Nutritional status and age of the host**

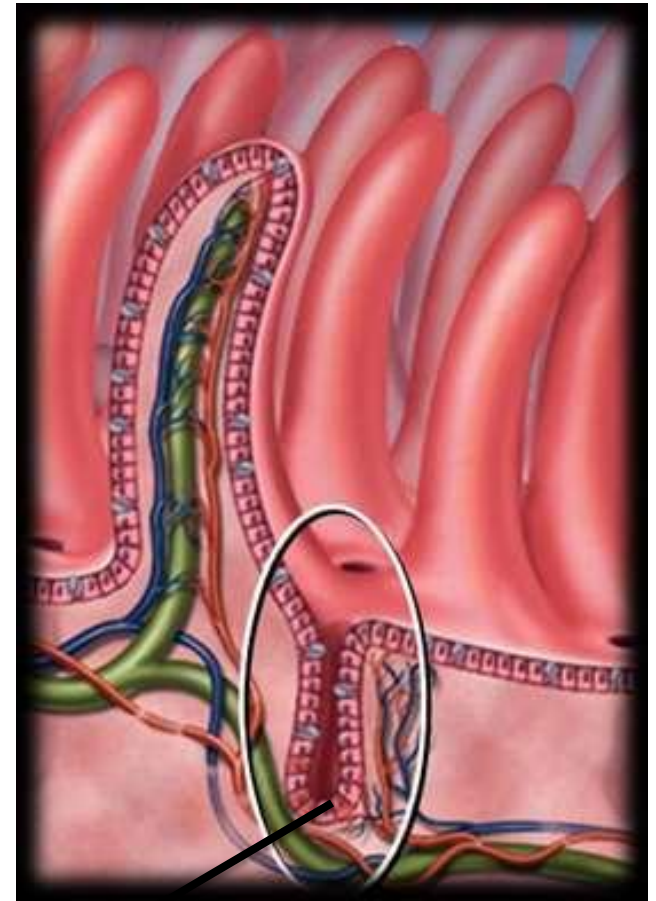
Pathogenesis

- The disease is seen in birds of 3-6 weeks old, before they have acquired immunity.
- The most virulent strains will cause diarrhoea and a sudden increase in flock mortality. Less virulent strains will result in poor growth and reduced feed efficiency
- Coccidiosis rarely occurs in layers and breeders as they have generally acquired immunity to this disease

- Pathogenicity depends on a number of factors
 - a. the number of host cells destroyed per infecting oocyst (which depends upon the number of merozoite generations and the number of merozoites per generation)
 - b. location of the parasite in the host tissues and within the host cells.
 - c. The size of the infecting dose or doses, the degree of reinfection
 - d. degree of acquired or natural immunity of the host

The most common and pathogenic form of the disease is caecal coccidiosis caused by *E. tenella* followed by intestinal coccidiosis caused by *E. necatrix*

- *E. necatrix* and *E. tenella* are the most pathogenic in chickens, because schizogony occurs in the lamina propria and crypts of Lieberkühn of the small intestine and ceca, respectively, and causes extensive hemorrhage
- Most species develop in epithelial cells lining the villi.



Intestinal Crypts

Clinical Signs

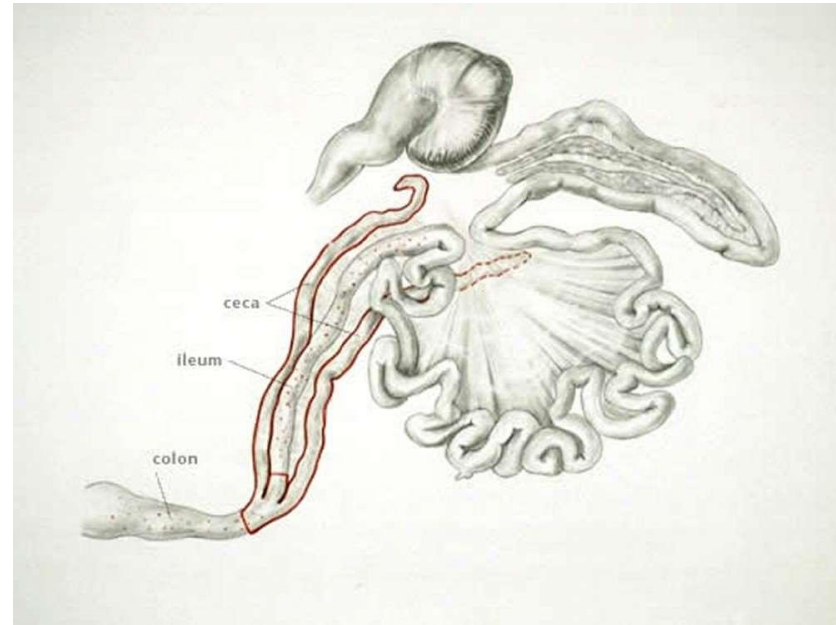
1. Decreased feed and water consumption.
2. Decreased growth rate with high percentage of visibly sickbirds.
3. Weight loss.
4. Severe diarrhea, bloody diarrhea.
5. Development of culls.
6. Decreased egg production.
7. High mortality.

8. Mild infections (subclinical) may cause depigmentation and potentially lead to secondary infection, particularly *Clostridium* spp infection.
9. Survivors of severe infections recover in 10–14 days but never recover lost performance
10. Lesions are present along the intestinal tract and often have a distinctive location and appearance that is useful in diagnosis.

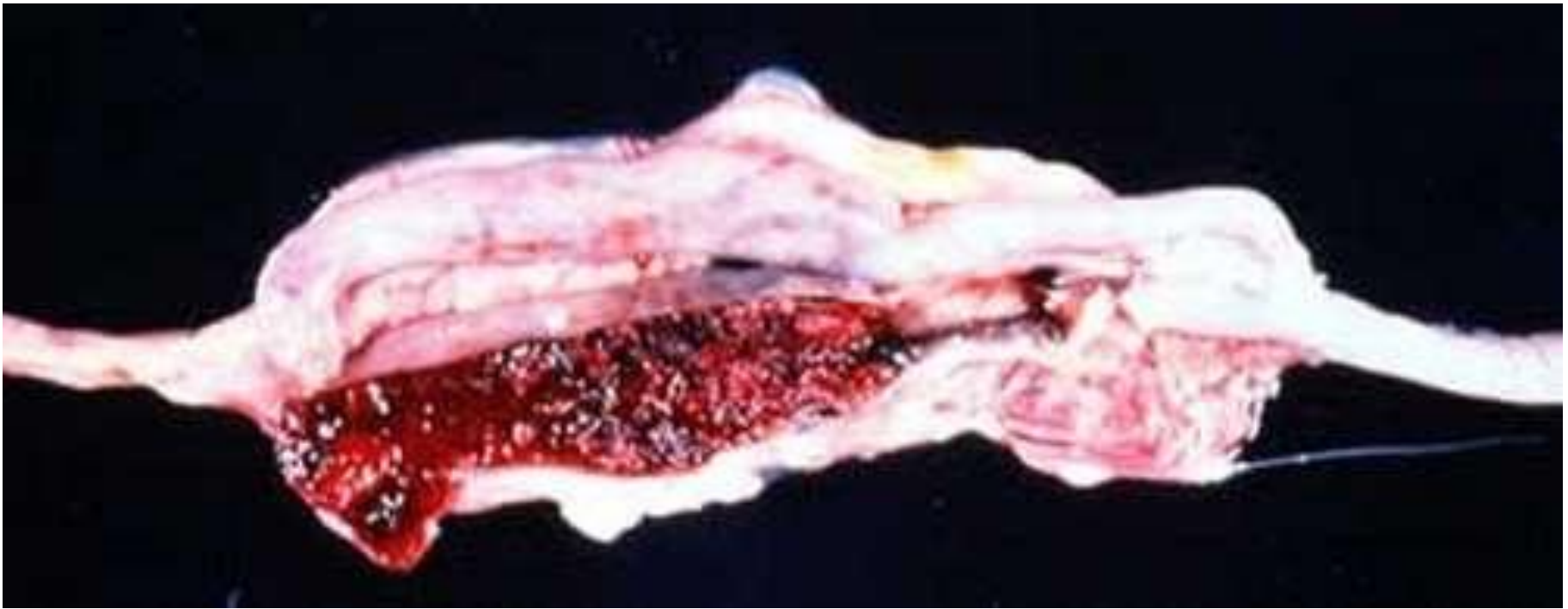Caecal coccidiosis

Characterized by:

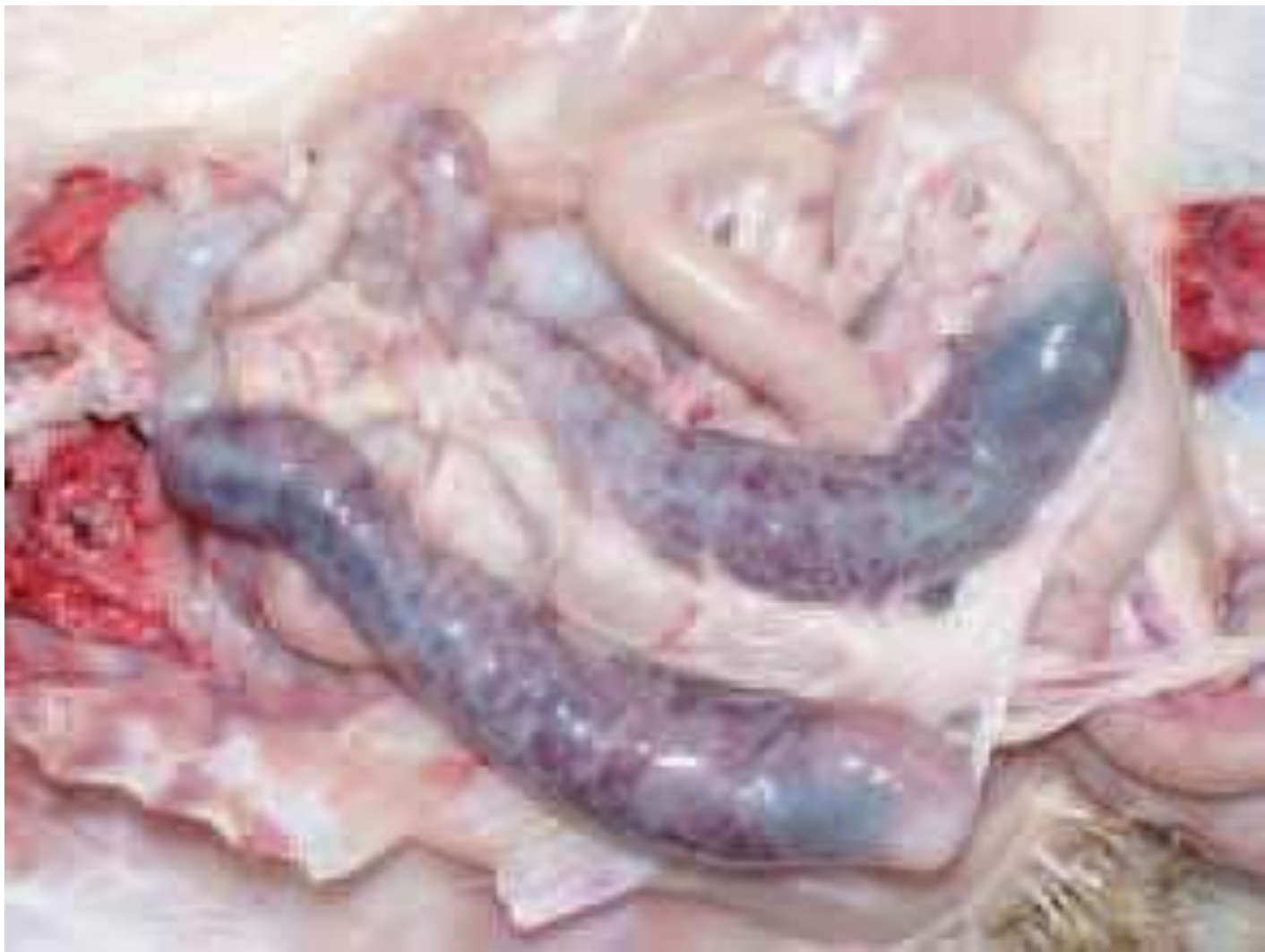1. Accumulation of blood in the caeca.
2. Bloody droppings.
3. Caecal cores, which are accumulations of clotted blood, tissue debris, and oocysts, may be found in birds surviving the acute stage.



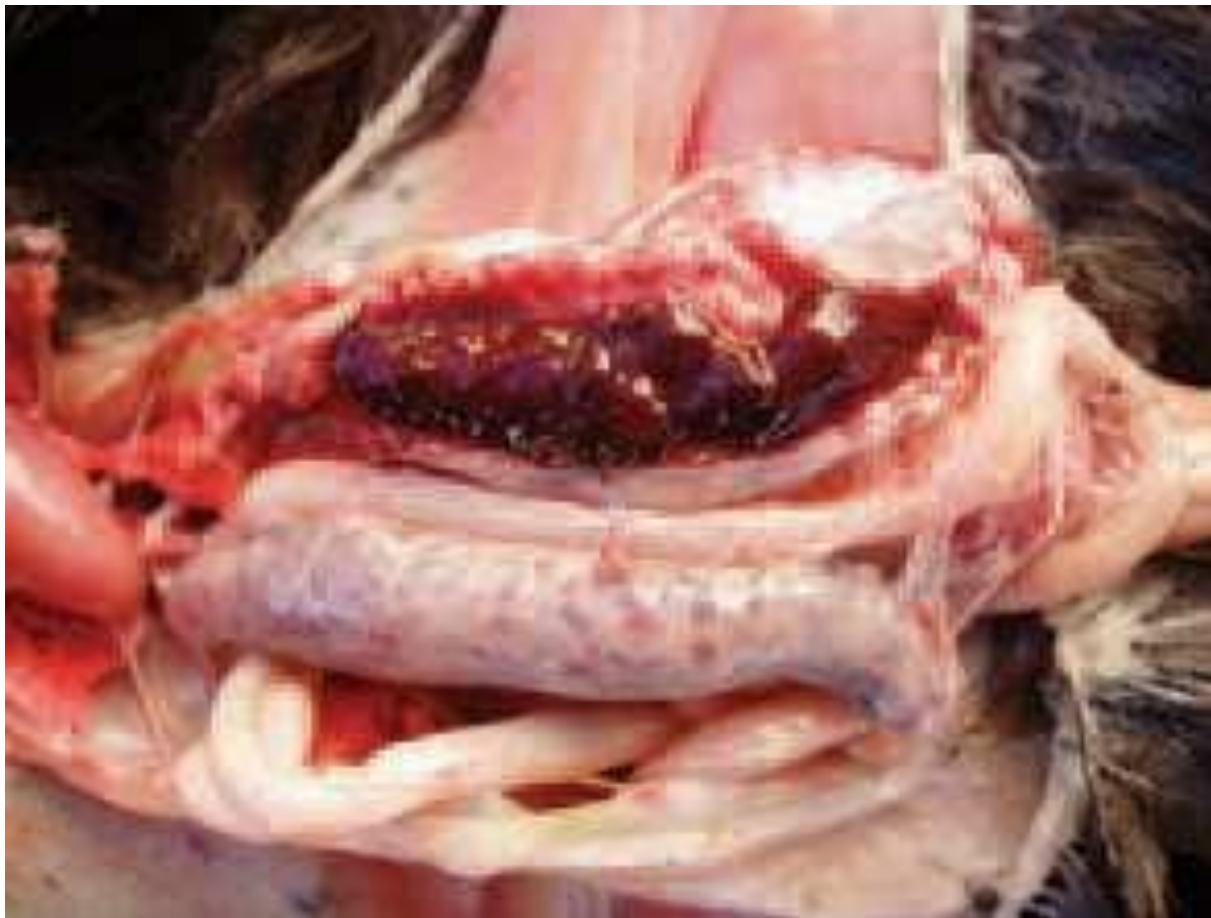Coccidiosis site parasitized by *E tenella* in poultry.



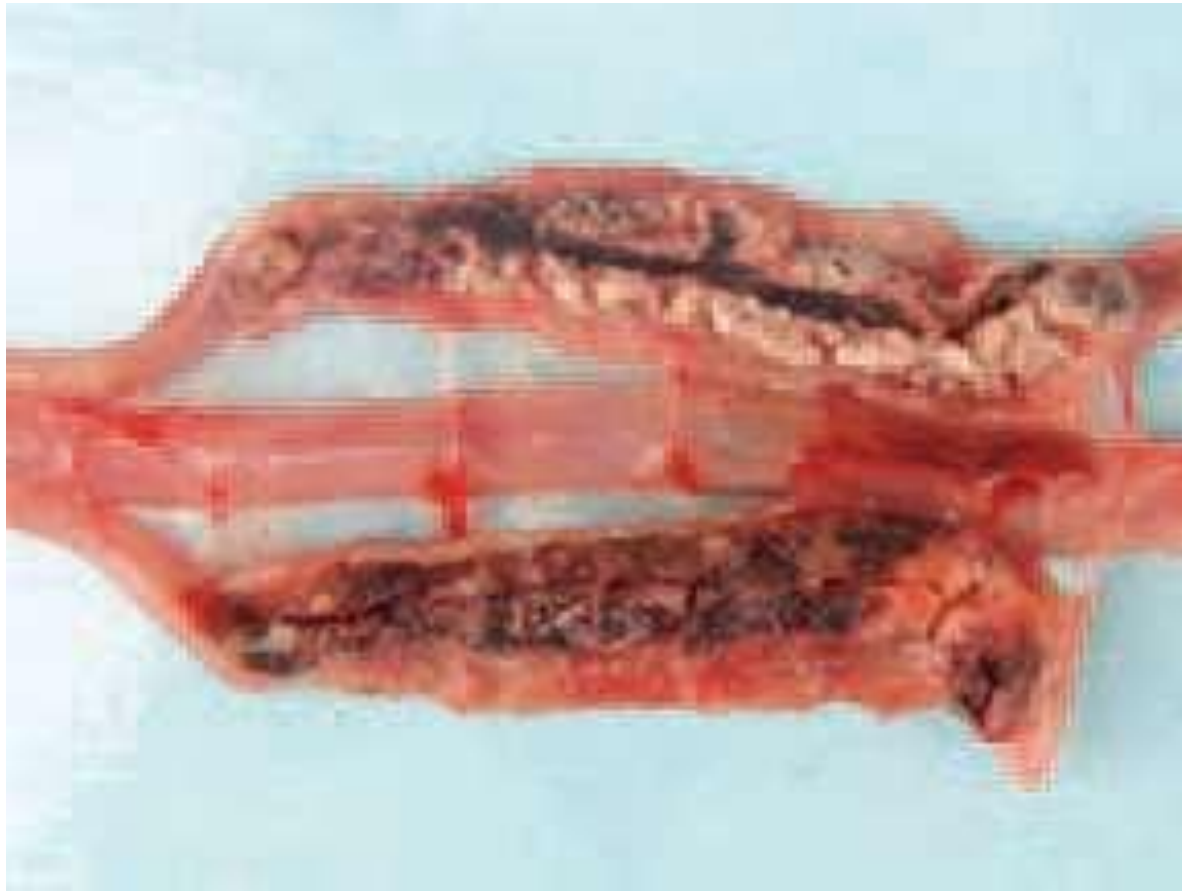Gross lesions of *E tenella* with frank hemorrhaging into caecal pouches in a broiler chicken.



E. tenella, a marked typhlitis is present and haemorrhages are seen through the intestinal wall.



E. tenella, caeca are filled with fresh or clotted blood.

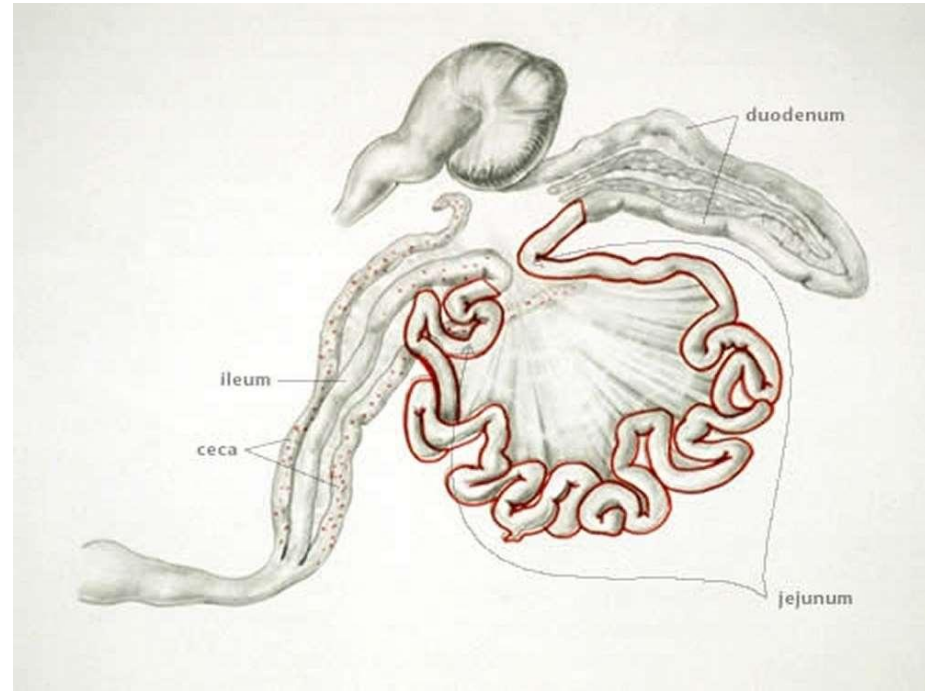


E. tenella, a later stage, the caecal content becomes thicker, mixed with fibrinous exudate and acquires a cheese like appearance.

Intestinal coccidiosis

E. necatrix

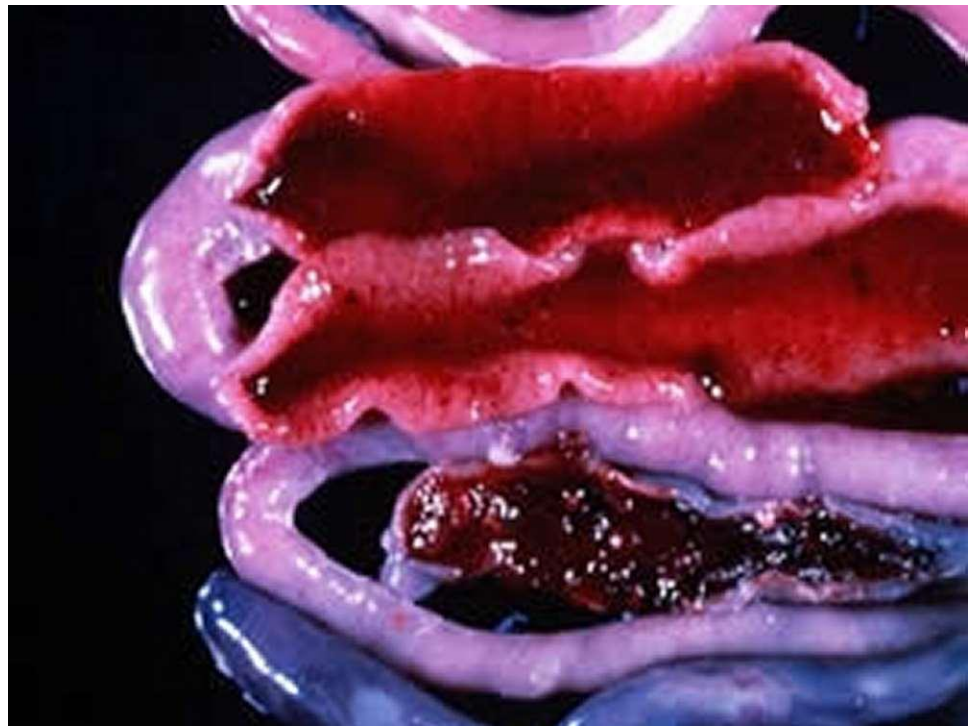- This species of *Eimeria* is highly pathogenic in chickens and it is often seen in birds from 9 to 14 weeks of age
- Mortality, severe weight losses, and feces with blood and mucus are frequent findings.



Coccidiosis site parasitized by *E necatrix* in poultry

- Small white spots, usually intermingled with rounded, bright or dull-red spots of various sizes, can be seen on the serosal surface.
- This appearance is sometimes described as “salt and pepper.”
- The white spots are diagnostic for *E necatrix* if clumps of large schizonts can be demonstrated microscopically.

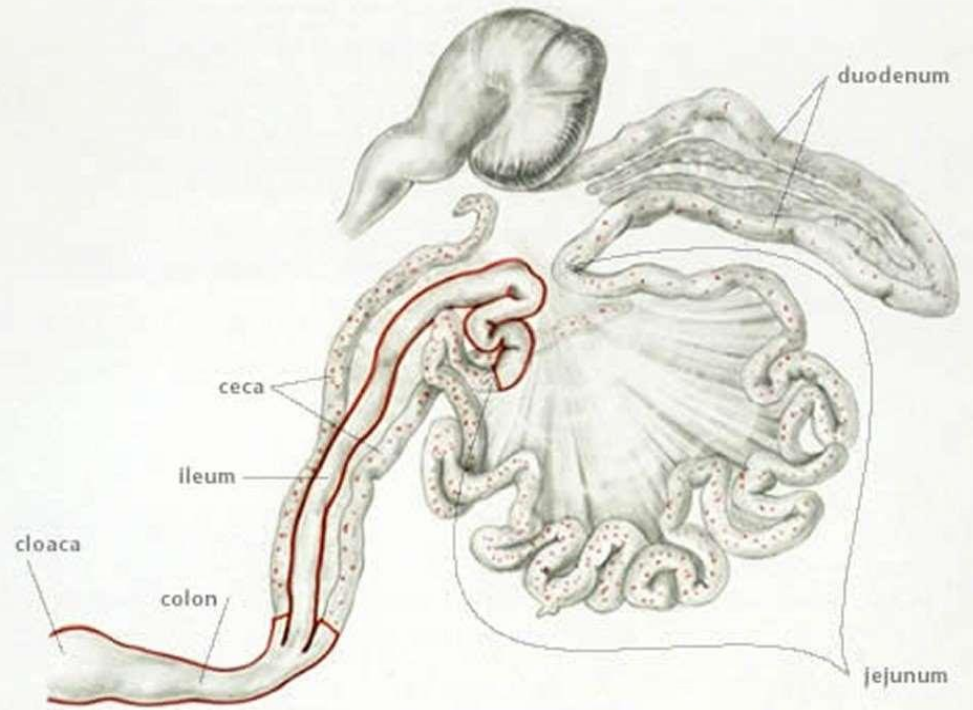
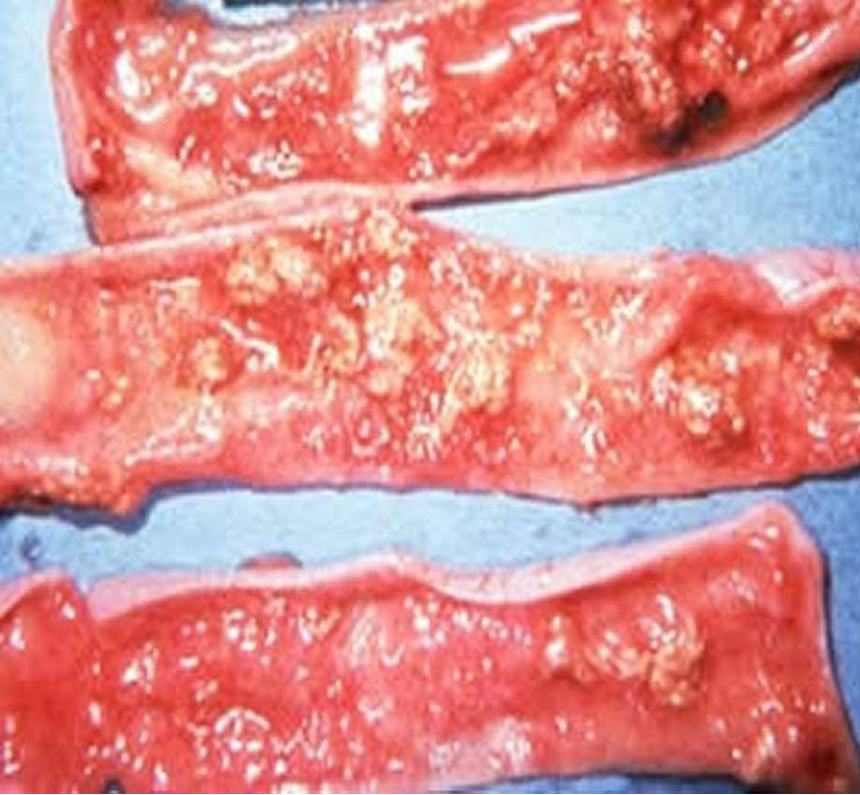
- In severe cases
 1. The intestinal wall is thickened.
 2. The infected area dilated to 2–2.5 times the normal diameter.
 3. lumen filled with blood, mucus, and fluid.
 4. marked dehydration.



Although the damage is in the small intestine, the sexual phase of the life cycle is completed in the caeca. Oocysts of *E necatrix* are found only in the ceca. Because of concurrent infections, oocysts of other species may be found in the area of major lesions, misleading the diagnostician.

Rectal coccidiosis

- Caused by *E brunetti*
- *E brunetti* is found in the lower small intestine, rectum, ceca and cloaca.
- In moderate infections, the mucosa is pale and disrupted but lacking in discrete foci, and may be thickened.
- In severe infections, coagulative necrosis and sloughing of the mucosa occurs throughout most of the small intestine.

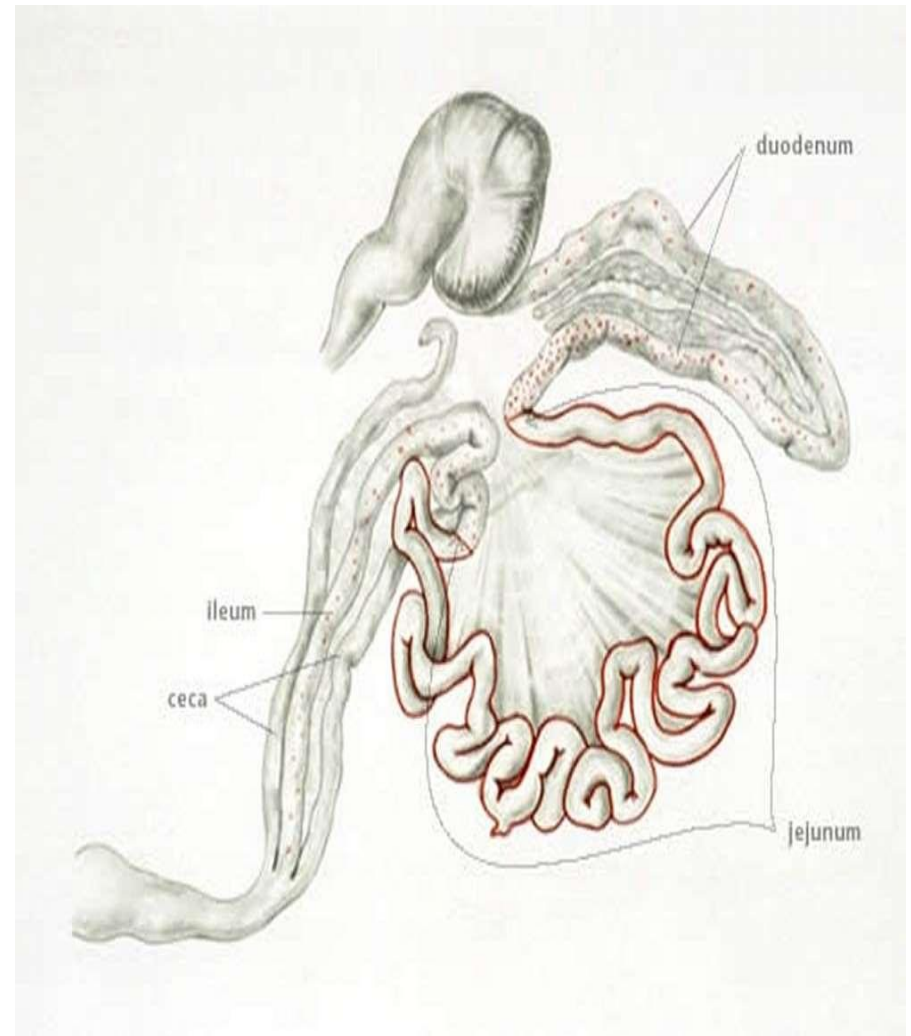


Coccidiosis site parasitized by *E brunetti* in poultry.

Gross lesions of *E brunetti* in small intestine of a broiler chicken

E. maxima

- *E maxima* develops in the small intestine, where it causes:
- Dilatation and thickening of the wall.
- Petechial hemorrhage.
- Reddish, orange, or pink viscous mucous exudate and fluid.
- midgut often has numerous whitish pinpoint foci, and the area may appear engorged.



Coccidiosis site parasitized by *E maxima* in poultry.

Speceies	Lesion	Clinical signs
<i>E. Acervulina</i>	numerous whitish transverse patches in the upper half of the small intestine	poor growth, an increase in culls, and slightly increased mortality
<i>E. Mitis</i>	pathogenic in the lower small intestine and lesions are indistinct resemble moderate infections of <i>E brunetti</i>	Moderate infection
<i>E. praecox</i>	infects the upper small intestine, does not cause distinct lesions watery intestinal contents	Less economic importance

Species	Site of development	Pathogenicity	Disease type
<i>E. necatrix</i>	Jejunum, ileum, caeca	+++++	Hemorrhagic
<i>E. tenella</i>	Caeca	+++++	Hemorrhagic
<i>E. brunetti</i>	Caeca and rectum	++++	Hemorrhagic
<i>E. maxima</i>	Jejunum, ileum	+++	Malabsorptive
<i>E. mitis</i>	Ileum	++	Malabsorptive
<i>E. acervulina</i>	Duodenum, ileum	++	Malabsorptive
<i>E. praecox</i>	Duodenum, jejunum	+	Malabsorptive

Diagnosis

- The location in the host, appearance of lesions, and the size of oocysts are used in determining the species present.
- Coccidial infections are readily confirmed by demonstration of oocysts in faeces or intestinal scrapings; however, the number of oocysts present has little relationship to the extent of clinical disease.

DIFFERENTIAL CHARACTERISTICS FOR 9 SPECIES OF CHICKEN COCCIDIA ©

DIAGNOSTIC CHARACTERISTICS IN RED

SPECIES OF DOUBTFUL VALIDITY

MACROSCOPIC LESIONS

CHARACTERISTICS	<i>E. acervulina</i>	<i>E. brunetti</i>	<i>E. maxima</i>	<i>E. mitis</i> †	<i>E. mivati</i> ‡	<i>E. necatrix</i>	<i>E. praecox</i>	<i>E. tenella</i>	<i>E. hagani</i>
ZONE									
PARASITIZED									

MACROSCOPIC LESIONS	light infection: whitish round lesions sometimes in ladder-like streaks heavy infection: plaques coalescing, thickened intestinal wall	coagulation necrosis mucoid, bloody enteritis in lower intestine	thickened walls, mucoid, blood - tinged exudate, petechiae	no discrete lesions in intestine, mucoid exudate	light infection: rounded plaques of oocysts heavy infection: thickened walls coalescing plaques	ballooning, white spots (schizonts), petechiae, mucoid blood - filled exudate	no lesions, mucoid exudate	onset: hemorrhage into lumen later: thickening, whitish mucosa, cores clotted blood	pinhead hemorrhages petechiae
---------------------	---	---	--	--	--	---	----------------------------	--	----------------------------------

MICROSCOPIC CHARACTERISTICS

MILLIMICRONS	10 20 30	10 20 30	10 20 30	10 20 30	10 20 30	10 20 30	10 20 30	10 20 30	
OOCYSTS REDRAWN FROM ORIGINALS									non available
LENGTH x WIDTH μ LENGTH = WIDTH =	AV = 18.3 x 14.6 17.7 - 20.2 13.7 - 16.3	24.6 x 18.8 20.7 - 30.3 18.1 - 24.2	30.5 x 20.7 21.5 - 42.5 16.5 - 29.8	15.6 x 14.2 11.7 - 18.7 11.0 - 18.0	15.6 x 13.4 11.1 - 19.9 10.5 - 16.2	20.4 x 17.2 13.2 - 22.7 11.3 - 18.3	21.3 x 17.1 19.8 - 24.7 15.7 - 19.8	22.0 x 19.0 19.5 - 26.0 16.5 - 22.8	19.1 x 17.6 15.8 - 20.9 14.3 - 19.5
OOCYST SHAPE AND INDEX-LENGTH/WIDTH	ovoid 1.25	ovoid 1.31	ovoid 1.47	subspherical 1.09	ellipsoid to broadly ovoid 1.16	oblong ovoid 1.19	ovoidal 1.24	ovoid 1.16	broadly ovoid 1.08
SCHIZONT, MAX IN MICRONS	10.3	30.0	9.4	15.1	17.3	65.9	20	54.0	
PARASITE LOCATION IN TISSUE SECTIONS	epithelial	2nd generation schizonts subepithelial	gametocytes subepithelial	epithelial	epithelial	2nd generation schizonts subepithelial	epithelial	2nd generation schizonts subepithelial	epithelial
MINIMUM PREPARENT PERIOD-HR	97	120	121	93	93	138	83	115	99
SPORULATION TIME MINIMUM (HR)	17	18	30	15	12	18	12	18	18

LIFE HISTORY CHARACTERISTICS

† = From Norton and Joyner (1980)
‡ = As described by Edgar and Siebold (1964)
© = Compiled from various sources

Prevention and treatment

- In poultry production several antimicrobials or antiprotozoals have been used for decades to **treat and prevent coccidiosis**. Depending on the type of poultry production, the approaches for an effective control of coccidiosis are different.

Methods of coccidiosis prevention or treatment:

- Coccidicides
- Coccidiostats
- vaccines

Coccidicides

- coccidiosis preventive program used usually aims for eliminating *Eimeria* completely from the gut by using coccidicides that kill the parasites.
- This results in optimal condition of the gastrointestinal tract, improving body weight, and reducing feed conversion

Coccidiostats

- In breeders and layers a different approach is usually needed. Due to the relatively long life cycle of these birds, development of protective immunity is desired. For this purpose a minimal degree of exposure to *Eimeria* is allowed.
- To achieve this objective, coccidiostats are used to arrest the development of the parasites at different stages of development allowing for a good balance between intestinal damage and appropriate exposure for immunity development.
- Of course, once the coccidiostats are withdrawn from the diet, the infecting parasites may resume their life cycle producing the clinical manifestations of the disease

Treatment

- sulfonamides are widely used
- sulfadimethoxine, sulfaquinoxaline, sulfamethazine, but they should not be used in layer hens.
- ionophores, which have an effect on membrane function of the parasite and act as both coccidiocides and coccidiostats (monensin)
- quinolones, which have an effect on energy metabolism of the parasite and act as both coccidiocides and coccidiostats (buquinolate)
- coccidiostatic thiamine analogs, which have an effect on co-factor synthesis for the parasite
- The supplementation of vitamins A and K promotes the recovery

Treatment	Example	Mechanism of Action
Ionophores	Lasalocid, Monensin, Narasinm Salinomycin, and Semduramicin	Disruption of ion gradient across the parasite cell membrane
Chemicals	Quinolone drugs (Decoquinatate and nequinatem buquinolate) Pyridones (Meticlorpindol)	Inhibition of parasite mitochondrial respiration
	Sulphonamides	Inhibition of the folic acid pathway
	Amprolium Diclazuril,	Competitive inhibition of thiamine uptake
	Halofuginone, and Robenidine	Mode of action unknown
	Nicarbazin	Inhibition of the development of the first and second generations of the schizont stage of the parasites

Antimicrobial resistance

- *Eimeria* parasites do develop drug resistance due to regular use of drugs.
- The resistance is greatly enhanced if the same family of antimicrobials is used for a long time within a defined area.
- Selective pressure will favour the few parasites within a population that are resistant, and within few rearing cycles the initial parasites would increase their population size to numbers able to induce clinical disease in a flock.

Shuttle programs

- A common practice to partially solve this problem is to use anti-coccidial 'shuttle' programs that rotate through different periods of the bird's life.
- This method has a good chance of eliminating the parasites that demonstrated resistance to a single antimicrobial.
- A variation of the same principle consists on changing coccidiostats between flocks.
- most suitable drug is used for starter, while another drug is used for grower and finisher. Drug withdrawal period is the most important consideration for drugs that will be used in finisher feeds.;
- Examples of reasonable shuttles are:
- Coban:Stenorol:Clinacox (an ideal winter program)
- Coxistac:Avatec - ideal for summer program
- Coxistac:Stenorol - winter or summer program
- Coxistac:Clinacox - winter or summer shuttle

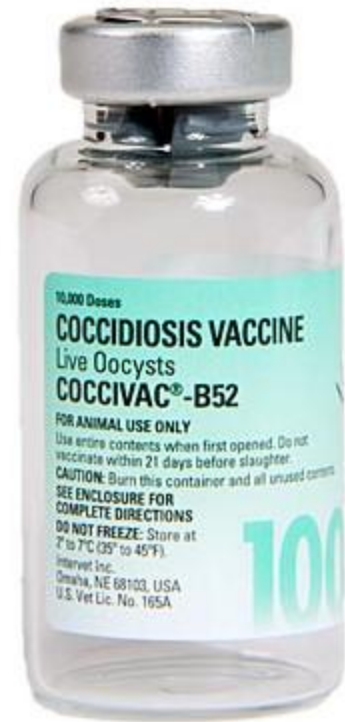Rotation Programme

- Rotation: means that a conscious decision is made to change the drug(s) used at a given time in the future i.e. every four months, after two crops, go to a winter and summer program etc. The alternative to a rotation program is a continuous program where the same drug(s) are used indefinitely, usually until a problem develops, or until a new product is introduced on the market. Shuttle programs fit into rotation programs
- An example of a rotation program (change every 4 months) would be:
 - 1st rotation (May-August) - ionophore i.e. Coxistac
 - 2nd rotation (September-December) - non-ionophore i.e. Clinacox
 - 3rd rotation (January-April) - shuttle Coban: Stenorol

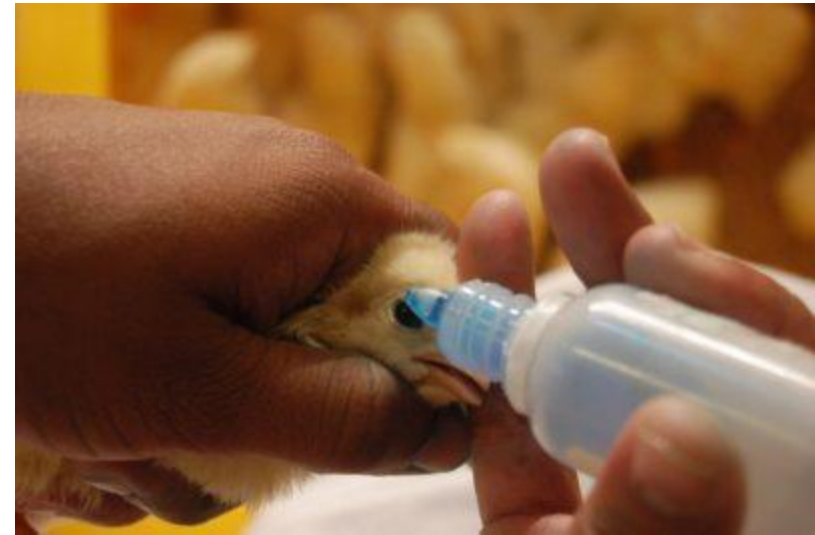Vaccines

Passive or active immune responses induce immunity in animals. This immunity can reduce the pathogenic effects of coccidiosis such as less macroscopically visible lesions, decreasing of oocyst production, and increasing performance of birds.

- The first commercial live coccidiosis vaccine was Coccivac® registered in the USA in 1952
- Currently, two types of vaccines are used with the aim of controlling coccidiosis in a chemical free way:
 - A) Live Non-attenuated
 - B) Live attenuated vaccines.
- The main risk of using live non-attenuated vaccines (Coccivac, Advent, Immucox, and Inovocox) is the live parasites that can develop a severe reaction in birds.
- Many times their use is accompanied by chemical treatments to control the inherent pathogenicity of the parasites .



- On the contrary, the success of live attenuated vaccines (Paracox and HatchPak Coccill) relies on the low risk of disease occurring because of the reduction in the proliferation of parasites and consequently a less damage in birds' tissue.
- Non-attenuated and attenuated vaccines may have different routes of administration (oral, eyes drops, in ovo) in birds and several *Eimeria* species as target.



Genetically engineered vaccines

- Genetically engineered Subunit vaccines consist of purified antigenic determinants obtained from *Eimeria* parasite.
- These vaccines are obtained from DNA recombinant technology and may consist of native antigens or recombinant proteins of various stages (sporozoites, merozoites, and gametes) of *Eimeria*.
- Distinct protective antigens used are micronemes, rhoptries, refractile bodies, merozoites, or gametocytes of *Eimeria* parasite








Coccidia of Turkey

- Generally there are seven species of coccidia infecting turkeys :
- *E. adenoides*, *E. dispersa*, *E gallopavonis*, *E meleagrimitis*, *E. innocua*, *E meleagridis*, and *E subrotunda* .
- *E. innocua*, *E. meleagridis*, and *E. subrotunda* are considered nonpathogenic.
- *E. adenoides*, *E. dispersa*, *E. gallopavonis*, and *E. meleagrimitis* are pathogenic

- Oocysts sporulate within 1–2 days after expulsion from the host; the prepatent period is 4–6 days.
- *E. adenoeides* and *E. gallopavonis* infect the lower ileum, ceca, and rectum. These species often cause mortality.
- The developmental stages are found in the epithelial cells of the villi and crypts. The affected portion of the intestine may be dilated and have a thickened wall.
- Thick, creamy material or caseous casts in the gut or excreta may contain enormous numbers of oocysts.

- *E meleagridis* chiefly infects the upper and mid small intestine.
- The lamina propria or deeper tissues may be parasitized, which may result in necrotic enteritis
- *E. dispersa* infects the upper small intestine and causes a creamy, mucoid enteritis that involves the entire intestine, including the ceca. Large numbers of gametocytes and oocysts are associated with the lesions.
- Common signs in infected flocks include reduced feed consumption, rapid weight loss, droopiness, ruffled feathers, and severe diarrhea. Wet droppings with mucus are common.
- Clinical infections are seldom seen in poults >8 wk old. Morbidity and mortality may be high

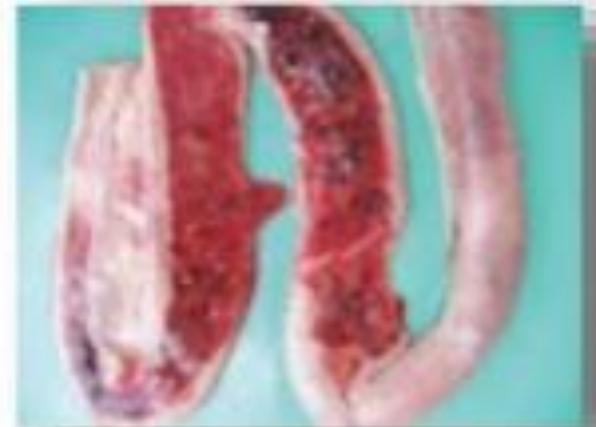Eimeria of Turkey

Characteristics	<i>E. adenoides</i>	<i>E. gallopavonis</i>	<i>E. meleagrimitis</i>	<i>E. dispersa</i>	<i>E. innocua</i>	<i>E. meleagridis</i>	<i>E. subrotunda</i>
Lesions							
Occasional lesions							
Coccidia, no lesions							
Location	ceca, rectum	lower intestine, ceca, rectum	small intestine	small intestine	upper small intestine	lower small intestine, ceca, rectum	upper small intestine
Macroscopic lesions	liquid feces with mucus and flecks of blood, loose whitish cecal cores	edema, ulceration of mucosal <i>ileum</i> , yellow exudate, flecks of blood in feces	spotty congestion and petechiae from <i>duodenum</i> to <i>ileum</i> , dilation of <i>jejunum</i> , casts	cream-colored serosal surface, dilation of intestine, yellowish mucoid feces	none	cream-colored ceca, formation of caseous plug, few petechial hemorrhages	none

Characteristic	E. adenoides	E. gallopavonis	E. meleagritis	E. dispersa	E. innocua	E. meleagris	E. subrotunda
Average length x width (μm)	25.6 x 16.6	27.1 x 17.2	19.2 x 16.3	26.1 x 21.0	22.4 x 20.9	22.4 x 18.1	21.8 x 19.8
Length	18.9 - 31.3	22.7 - 32.7	15.8 - 26.9	21.8 - 31.1	18.57 - 25.86	20.3 - 30.8	16.48 - 26.42
Width	12.6 - 20.9	15.2 - 19.4	13.1 - 21.9	17.7 - 23.9	17.34 - 24.54	15.4 - 20.6	14.21 - 24.44
Oocyst shape and index	ellipsoidal	ellipsoidal	ovoid	broadly oval	subspherical	ellipsoidal	subspherical
Length/width	1.54	1.52	1.17	1.24	1.07	1.34	1.10
Minimum sporulation (hrs.)	24	15	18	35	<45	24	48
Minimum prepatent period (hrs.)	103	105	103	120	114	118	95
Refractile body	yes	yes	yes	no	no	yes	no
Relative pathogenicity	++++	++++	++++	+	none	none	none

Coccidia of Duck

- A large number of specific coccidia have been reported in both wild and domestic ducks
- Presence of *Eimeria*, *Wenyonella*, and *Tyzzeria* spp has been confirmed
- *T. perniciososa* is a known pathogen that balloons the entire small intestine with mucohemorrhagic or caseous material
- Pathogenesis resembles *E. necatrix*



Content mixed with fresh or clotted blood

Coccidia of Geese

The best known coccidial infection of geese is that produced by *E. truncata*, in which the kidneys are enlarged and studded with poorly circumscribed, yellowish white streaks and spots.

The tubules are dilated with masses of oocysts and urates.

Mortality may be high.

At least five other *Eimeria* spp have been reported to parasitize the intestine of geese, but these are of lesser importance



Control by management practices

- Maintain vigilance and treat as soon as the first symptoms are seen
- Keep different age groups separate
- Ensure that litter is dry but not dusty – avoid any causes of wet litter
- Keep litter dry round watering points – do not allow drinkers to overflow
- Ensure high standards of hygiene of personnel
- Ensure good hygiene of feeding and drinking equipment Keep raising the level of drinkers as chicks grow to reduce fouling
- Vaccinate if the risks of disease are high



Thank you